

Lyon University 

Meniscal Roots Lesions

Ph Neyret -Tim Lording

E Servien
S Lustig
C Debette
V Villa

5th Advanced Course on Knee Surgery
January 24-27, 2014 Val d'Isère
Val d'Isère 2014

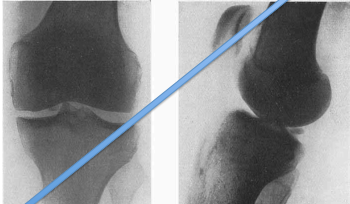


Meniscal Root Lesions

Philippe Neyret
Tim Lording
5th Advanced Course on Knee Surgery
Val D'Isère 2014

Historical Perspective


- First description of meniscal avulsion in 1934



Burrows HJ, Two cases of ossification in the internal semilunar cartilage. BJS 1934; 21(83): 404-410

Historical Perspective

- 1991 cases reports recognised:
 - Meniscal ossicle as avulsion # at arthroscopy
 - Meniscal extrusion on MRI



Berg EE, The meniscal ossicle: the consequence of a meniscal avulsion. Arthroscopy 1991; 7(2): 241-243
Pagnani et al, Extrusion of the medial meniscus. Arthroscopy 1991; 7(3): 297-300

Historical Perspective

- 1996 significance suggested in studies into meniscal allograft fixation
 - Graft with single horn fixation showed contact area and pressures between intact knee and total meniscectomy

Chen Ml et al, Is it important to secure the horns during lateral meniscal transplantation? A cadaveric study. Arthroscopy 1996; 12(2): 174-181

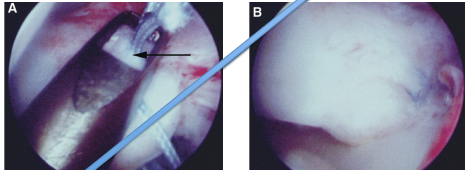
Historical Perspective

- 2004 radiologic studies linked:
 - Root tears
 - Meniscal extrusion
 - Development of degenerative changes

Lerer DB et al, The role of meniscal root pathology and radial meniscal tear in medial meniscal extrusion. Skeletal Radiology 2004; 33(10): 569-574
Costa CR et al, Medial meniscal extrusion on knee MRI: is extent associated with severity of degeneration or type of tear? Am J Roentgenol 2004; 183(1): 17-23

Historical Perspective

- 2004-7 first reports of techniques for avulsion repairs



West RV et al, Lateral meniscal root tears associated with anterior cruciate ligament injury: Classification and management (S100). Arthroscopy 2004;20: e32-e33 (Abstr)
 Petersen W, Sartori T, Avulsion injury to the medial horn of the lateral meniscus, Technique for arthroscopic refixation. Unfallchirurg 2006; 109(11): 984-987 (in German)
 Marziani W, Kumar BA, Primary repair of medial meniscal avulsions: 2 case studies, AJSM 2007; 35(8): 1380-1383

Importance of Root Tears

- First suggested by studies on meniscal transplants
- Alters load distribution and kinematics
- Effect similar to total meniscectomy

Chen MI et al, Is it important to secure the horns during lateral meniscal transplantation? A cadaveric study. Arthroscopy 1996; 12(2): 174-181
 Allaire R et al, Biomechanical consequences of a tear of the posterior root of the medial meniscus. Similar to total meniscectomy, JBKS Am 2008, 90(9), 1922-1931
 Marzo JM, Effects of Medial Meniscus Posterior Horn Avulsion and Repair on Tibiofemoral Contact Area and Peak Contact Pressure: With Clinical Implications, AJSM 2008; 37(1): 124-129
 Schillhammer CK et al, Repair of lateral meniscus posterior horn detachment lesions: A biomechanical evaluation, AJSM 2012; 40(11): 2604-2609

What lesions do we see?

- Lateral meniscus
 - Posterior horn avulsion/tear with ACL rupture
 - Isolated posterior horn injury
- Medial meniscus
 - Acute Radial root tear/avulsion
 - May occur in multilig injury with MCL grade III
 - Root tear with OA

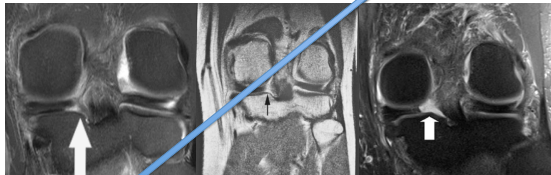
Indications for surgery

- Lateral meniscus
 - Avulsion with ACLR V
 - Isolated avulsion?
- Medial meniscus
 - Radial root tear/avulsion V
 - Root tear with OA x

Shelbourne KD et al, Long-Term Evaluation of Posterior Lateral Meniscus Root Tears Left In Situ at the Time of Anterior Cruciate Ligament Reconstruction, AJSM 2011; 39(7): 1439-1443
 Musahl V et al, The Effect of Medial Versus Lateral Meniscectomy on the Stability of the Anterior Cruciate Ligament-Deficient Knee, AJSM 2010; 38(8): 1591-1597
 Vyas D, Hamner CD, Meniscus root repair, Sports Med Arthrosc 2012; 20(2): 86-94

Diagnosis

- May be seen on MRI scans

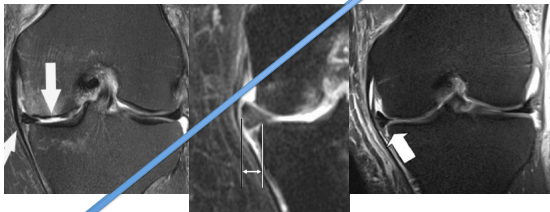


- Only visible in ~70%

Ozkoc G et al, Radial tears in the root of the posterior horn of the medial meniscus, KSSTA 2008; 16(9): 849-854

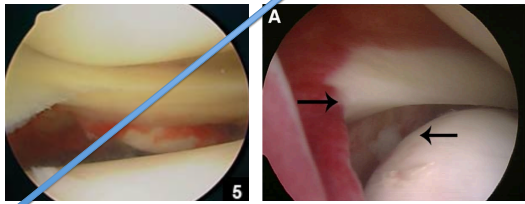
Diagnosis

- Suspect with meniscal extrusion



Diagnosis

- May be overlooked at arthroscopy
 - Meniscus intact but elevated

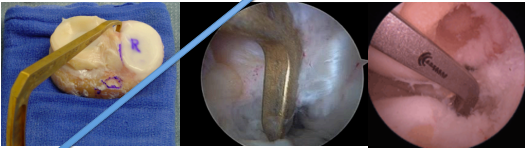


Elements of Repair

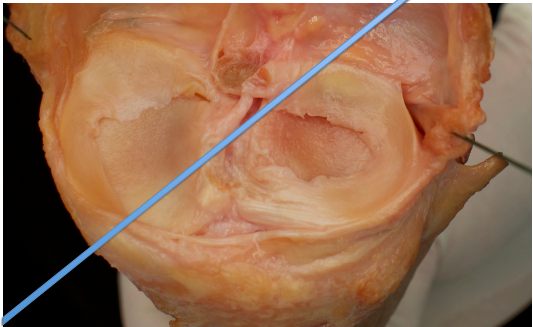
- Access to lesion
- Drilling of tunnel
- Passage of sutures
- Fixation
- Rehabilitation

Tunnel Drilling

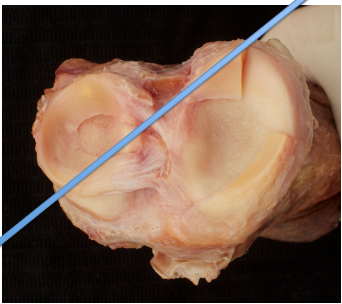
- Using ACL drill guide
 - Guide wire then 4.5mm “End button” drill
- Access easy on lateral side in ACL rupture



Courtesy R Smigielski

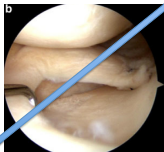


Courtesy R Smigielski



Tunnel Drilling

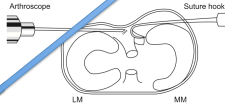
- For medial root tears, tunnel should be placed so as to avoid “over-tightening” the meniscus



Seo JH et al, Effect of repair of radial tears at the root of the posterior horn of the medial meniscus with the pullout suture technique: A biomechanical study using porcine knees, Arthroscopy 2009; 25(11): 1281-1287
Stärke C et al, The effect of nonanatomic repair of the meniscal horn attachment on meniscal tension: A biomechanical study, Arthroscopy 2010; 26(3): 358-365

Access to Lesion

- Trans-osseous techniques usually possible through standard portals
 - Repairs also described with 1 or 2 posteromedial portals or posterior trans-septal portal



Wang KH et al. Arthroscopic direct repair for a complete radial tear of the posterior root of the medial meniscus. Clin Orthop Rel Res. 2011; 3(4): 332-335
 Anh JH et al. A pull out suture for transection of the posterior horn of the medial meniscus: using a posterior trans-septal portal. KSSTA 2007; 15(12): 1510-1513

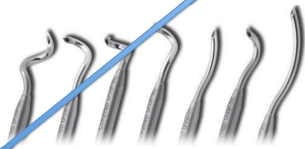Preparation of Insertion Site

- ? Burr or curette insertion site to promote healing
- Anatomical fixation for avulsions
- ? In-situ fixation for root tears to prevent tension changes

Seo JH et al. Effect of repair of radial tears at the root of the posterior horn of the medial meniscus with the pullout suture technique: A biomechanical study using porcine knees. Arthroscopy 2009; 25(11): 1281-1287
 Stürke C et al. The effect of nonanatomic repair of the meniscal horn attachment on meniscal tension: A biomechanical study. Arthroscopy 2010; 26(3): 358-365

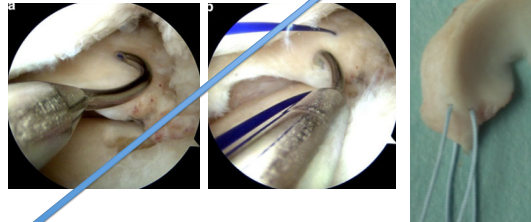
Passage of Sutures

- Sutures placed through meniscus with instruments designed for shoulder surgery
 - Eg Spectrum suture passer (ConMed)



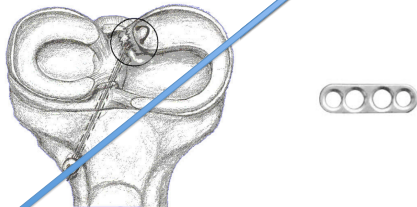
Passage of Sutures

- PDS suture passed
- Used to shuttle fibrewire



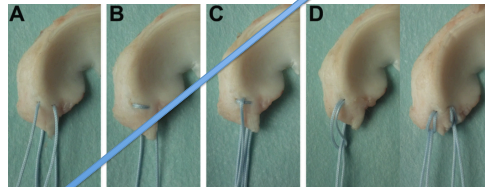
Passage of sutures

- Sutures pulled through tunnel and tied over endobutton



Passage of Sutures

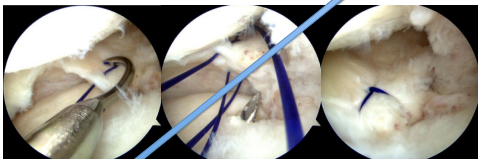
- Numerous techniques possible
 - Simple to complex



Feuchtmayr et al. Biomechanical evaluation of different suture techniques for arthroscopic transistibial pull-out repair of posterior medial meniscus root tears. AJSM 2013 Advance online publication doi:10.1177/0363546513502464

Passage of Sutures

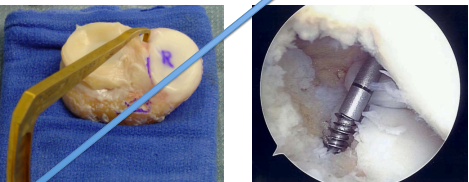
- Modified Mason-Allen strongest in-vitro



Lee DW et al, Meniscus root fixation using a modified Mason-Allen stitch, KSSTA 2012; 21(3); 654-657
 Feucht MJ et al, Biomechanical evaluation of different suture techniques for arthroscopic trans tibial pull-out repair of posterior medial meniscus root tears, AJSM 2013 Advance online publication doi: 10.1177/0363546513502464


Fixation

- 2 possibilities
 - Trans-osseous pull-out techniques
 - Suture anchors



Trans-osseous Techniques

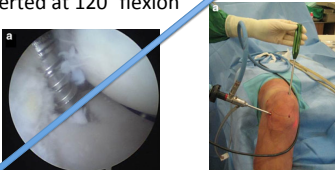
- Using ACL drilling guide
- Has been described using “Flip Cutter” to create a bony socket



Nicholas SJ, A new surgical technique for arthroscopic repair of the meniscus root tear, KSSTA 2009; 17(12); 1433-1438

Suture Anchors

- Inserted through posteromedial portal
- Medial quadriceps portal also described
 - Inserted at 120° flexion




- Not described for lateral lesions

Hong W et al, Arthroscopic, suture anchor repair through a novel medial quadriceps portal for medial meniscal root tear, KSSTA 2012; 20(12); 2391-2394

Alternative fixation

- Techniques described for suture anchor fixation medially
 - Requires additional posteromedial portal



Fixation

- Biomechanical studies suggest suture anchor technique is superior
- A prospective comparison study found no difference at 2 years

Feucht MJ et al, Biomechanical comparison between suture anchor and trans tibial pull-out repair for posterior medial meniscus root tears, AJSM 2013, Advance online publication doi:10.1177/0363546513502946
 Kim JH et al, Arthroscopic suture anchor repair versus pullout suture repair in posterior root tear of the medial meniscus: A prospective comparison study, Arthroscopy 2011; 27(12); 1644-1653

Rehabilitation

- Repairs not as strong as native root
- May elongate early
- Recommendation for conservative rehabilitation approach

Kopf S et al, Meniscal root suturing techniques: Implications for root fixation, *AJSM* 2011; 39(10): 2141-2146
 Röpke EF et al, Biomechanical evaluation of meniscal root repair: a porcine study, *KSSTA* 2013, Advance online publication doi:10.1007/s00167-013-2589-6

Does It Work?

- In-vitro studies demonstrate correction of tibiofemoral contact pressures and contact areas to normal for both compartments
- Good short term clinical results for medial root tears – incomplete healing in ~50%

Schilhammer CK et al, Repair of lateral meniscus posterior horn detachment lesions: A biomechanical evaluation, *AJSM* 2012; 40(14): 2604-2609
 Marzo JM, Effects of Medial Meniscus Posterior Horn Avulsion and Repair on Tibiofemoral Contact Area and Peak Contact Pressure With Clinical Implications, *AJSM* 2008; 37(1): 124-129
 Kim JH et al, Arthroscopic suture anchor repair versus pullout suture repair in posterior root tear of the medial meniscus: A prospective comparison study, *Arthroscopy* 2011; 27(12): 1644-1653

Does It Work?

- Little evidence for lateral avulsion repair
 - 1 natural history study of isolated posterior root tear suggests benign course
 - May be important in combination with ACL reconstruction
 - Rotational control
 - Chondral protection

Shelbourne KD et al, Long-term Evaluation of Posterior Lateral Meniscus Root Tears Left In Situ at the Time of Anterior Cruciate Ligament Reconstruction, *AJSM* 2011; 39(7): 1439-1443
 Musahl V et al, The Effect of Medial Versus Lateral Meniscectomy on the Stability of the Anterior Cruciate Ligament-Deficient Knee, *AJSM* 2010; 38(8): 1591-1597

